

Brain Tumor in an In Vitro Fertilization–Facilitated Pregnancy: Fourth Ventricle Anaplastic Ependymoma in the Second Trimester

Nurzhan Ryskeldiyev¹ Gabit Olenbay¹ Raushan Auezova¹ Tim Killeen² Nurgul Aldiyarova¹
Zauresh Akhmetzhanova¹ Evaldas Cesnulis² Serik Akshulakov¹

¹National Centre for Neurosurgery, Astana, Kazakhstan

²Department of Neurosurgery, Klinik Hirslanden, Zurich, Switzerland

Address for correspondence Nurzhan Ryskeldiyev, MD, National Center for Neurosurgery, Turan Avenue 34/1, 0100000 Astana, Kazakhstan (e-mail: raim@ramber.ru).

J Neurol Surg Rep 2016;77:e86–e88.

Abstract

Keywords

- ▶ brain tumor
- ▶ anaplastic ependymoma
- ▶ pregnancy
- ▶ in vitro fertilization

We present a case of fourth ventricle anaplastic ependymoma in a pregnancy which was the first result of three rounds of in vitro fertilization (IVF) and embryo transfer. Whether hormonal treatment can directly or indirectly precipitate brain tumors to develop or become symptomatic is unclear.

Introduction

Brain tumors occur rarely in pregnant women but are nevertheless the third commonest cause of cancer death in women aged 15 to 39 years.¹ Treatment of brain tumors during pregnancy is a difficult task which presents a major dilemma—how to save the life of the mother and that of the growing fetus? Specialists may be presented with a patient who has an overwhelming desire to continue the pregnancy, while decision making may be complicated by the involvement of a uniquely broad multidisciplinary team consisting of obstetricians, surgeons, oncologists, anesthesiologists, neonatologists, and other disciplines.

We present a retrospective clinical case of a fourth ventricle anaplastic ependymoma with brain stem invasion in a woman who presented in the 20th week of a pregnancy initiated via in vitro fertilization and embryo transfer (IVF-ET). We discuss aspects of her treatment which included surgical resection of the tumor, resulting in a favorable outcome for mother and child.

Case Report

A 33-year-old patient was admitted to a neurosurgical tertiary referral center with constant, intense headaches, dizziness, nausea, and vomiting. She was in the second trimester of a long-awaited first pregnancy, which came after 11 years of attempts at conception and was the result of a third cycle of IVF-ET. Her symptoms began in the third week of pregnancy as pulsating headaches which were worse in the morning, responsive to oral analgesics and occasionally accompanied by nausea, and were attributed to early pregnancy toxemia.

In the second trimester, deterioration in the form of worsened headache, nausea, dizziness, gait disturbance, photophobia, and recurrent vomiting ensued. Magnetic resonance imaging (MRI), performed at a secondary hospital (▶ Fig. 1A, B), revealed a 2 × 3 cm tumor arising in the region of the fourth ventricle, invading the brain stem and causing obstructive hydrocephalus. She was transferred emergently to our center for further assessment.

A multidisciplinary meeting was held with neurologists, neurosurgeons, anesthesiologists, and obstetricians in which the

received
November 14, 2015
accepted after revision
March 16, 2016

DOI <http://dx.doi.org/10.1055/s-0036-1583311>.
ISSN 2193-6358.

© 2016 Georg Thieme Verlag KG
Stuttgart · New York

License terms



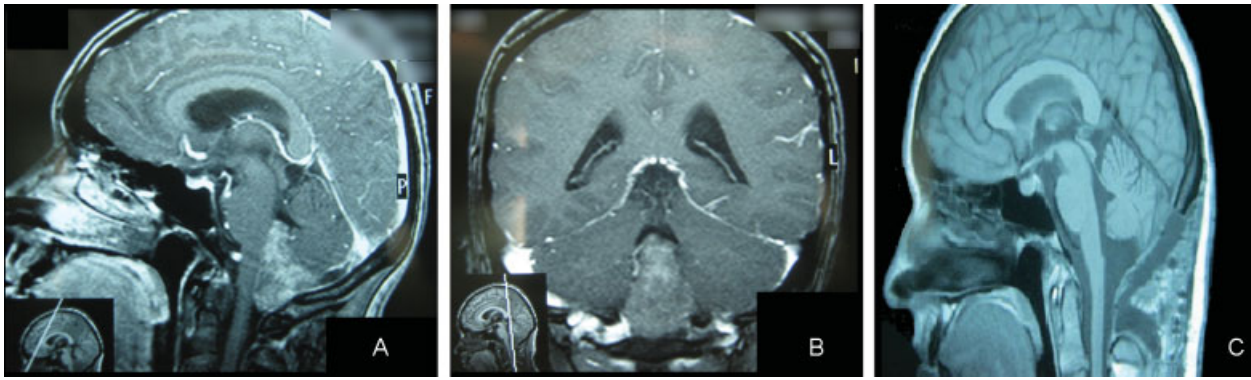


Fig. 1 (A) A sagittal T1-weighted gadolinium-enhanced MRI scan of the head of a pregnant 33-year-old woman, demonstrating a contrast-enhancing lesion in the posterior fossa invading the brain stem and causing mass effect and obstructive hydrocephalus. (B) A coronal MRI scan of the same lesion. (C) A T1-weighted sagittal MRI scan of the same patient 2 months after total resection of the lesion confirmed to be an anaplastic ependymoma arising from the fourth ventricle. MRI, magnetic resonance imaging.

strong desire of the patient to continue the pregnancy was taken into account. In light of the hydrocephalus, the deteriorating neurological condition of the patient and signs of intrauterine fetal distress, intervention in the form of removal of the tumor with intraoperative monitoring of the fetus was planned.

Informed consent was provided by the patient and she underwent a posterior fossa craniotomy and microsurgical resection of the tumor. Particular attention was paid to the positioning of the patient on the table. We normally perform posterior fossa tumor excision in the seated position but, in this case, the patient was positioned in the left lateral position to reduce the risk of aortocaval compression and thromboembolic complications.

General anesthesia was initiated using low-flow inhaled isoflurane (mean alveolar concentration 0.4–0.6) and maintained with 200 mg of 2% propofol with 0.1 mg of 0.005% fentanyl intravenously. Muscle relaxation was achieved with 50 mg of atracurium besilate. The surgery lasted 3 hours 40 minutes and intraoperative blood loss was approximately 300 mL.

Histological examination of the resected tumor confirmed a grade III anaplastic ependymoma with extensive hemorrhage. The postoperative period was uneventful for mother and fetus, and the patient was discharged on the 11th postoperative day. Follow-up MRI with contrast was performed at 2 months with no evidence of tumor recurrence (► Fig. 1C).

The patient remained under the careful supervision of neurologists, neurosurgeons, and obstetricians for 4 months until giving birth to a healthy baby girl weighting 3,200 g at 39 weeks' gestation by cesarean section. There was no evidence of tumor recurrence on 2-year follow-up MRI.

Discussion

Fortunately, brain tumors occur only rarely during pregnancy. Meningiomas have been observed in some pregnant women to become symptomatic during pregnancy, followed by postpartum remission and recurrence in subsequent pregnancies, arguably due to direct hormonal influence.² Similar symptomatic exacerbations have been observed in glial tumors.²

The literature on the incidence of brain tumors during pregnancy in the context of IVF is critically sparse, with a single case report of glioblastoma in the third trimester of an IVF pregnancy. Malignant transformation of a histologically verified breast fibroadenoma following hormonal stimulation for IVF has also been documented.

The physiological changes associated with pregnancy may mask the signs and symptoms of a brain tumor. Symptoms such as headache, nausea, vomiting, seizures, fainting, and cognitive impairment are very similar to toxemia of early pregnancy, preeclampsia, and eclampsia and may, therefore, result in delay and difficulty in the diagnosis of the true cause of these symptoms. Health professionals involved in the care of pregnant woman should maintain oncological vigilance in cases involving assisted reproductive techniques such as IVF, especially in those women with a previously diagnosed tumor of any kind.

Despite growing clinical experience in the treatment of cancer during pregnancy, knowledge about optimal management remains limited. The need for multicenter studies to provide an evidence base for this multidisciplinary problem continues to grow and initiatives such as the International Network on Cancer, Infertility and Pregnancy³ can play a significant role in facilitating informed decisions.

Conclusion

The diagnosis and treatment of brain tumors during pregnancy presents a challenge to clinicians as the safest approach for both mother and fetus may not always be clear. The case presented here demonstrates that the existence of neurosurgical pathology requiring urgent intervention is not an absolute contraindication to continuation of the pregnancy. Success in such cases is based on close cooperation between members of the multidisciplinary team. The possibility of an effect of hormone stimulation on the growth and malignant transformation of neoplasms during IVF therapy should be borne in mind.

Conflict of Interest

None.

References

- 1 Office for National Statistics. Summary Tables, England and Wales. Death Registered Summary Tables, England and Wales, 2013. Available at: <http://www.ons.gov.uk/ons/rel/vsob1/death-reg-sum-tables/2013/rft-deaths-summary-tables-2013.xls>. Accessed June 5, 2015
- 2 Isla A, Alvarez F, Gonzalez A, García-Grande A, Perez-Alvarez M, García-Blazquez M. Brain tumor and pregnancy. *Obstet Gynecol* 1997;89(1):19–23
- 3 International Network on Cancer, Infertility and Pregnancy. Cancer in Pregnancy Available at: www.cancerinpregnancy.org. Accessed June 5, 2015